

Differences in Fabry Cardiomyopathy Between Female and Male Patients

Consequences for Diagnostic Assessment

Markus Niemann, MD,*† Sebastian Herrmann, MD,*† Kai Hu, MD,*
Frank Breunig, MD,* Jörg Strotmann, MD,* Meinrad Beer, MD,‡
Wolfram Machann, MD,‡ Wolfram Voelker, MD,* Georg Ertl, MD,*†
Christoph Wanner, MD,* Frank Weidemann, MD*†

Würzburg, Germany

OBJECTIVES We hypothesized that Fabry cardiomyopathy in female patients might differ substantially from that in male patients and sought to prove this hypothesis in a large cohort consisting of 104 patients with Fabry disease.

BACKGROUND Fabry cardiomyopathy in male patients is characterized by left ventricular (LV) hypertrophy, impaired myocardial function, and subsequent progressive myocardial fibrosis. In contrast, the occurrence of these 3 cardiomyopathic hallmarks in female patients remains unknown.

METHODS In 104 patients (58 females, age 42 ± 16 years; 46 males, age 42 ± 13 years) with genetically proven Fabry disease, LV hypertrophy, regional myocardial deformation and myocardial fibrosis were assessed by standard echocardiography, strain rate imaging, and cardiac magnetic resonance (CMR) imaging–guided late enhancement (LE).

RESULTS In men, end-diastolic left ventricular wall thickness (LVWT) ranged from 6 to 19.5 mm (LV mass CMR 55 to 200 g/m²), and LE was never seen with LVWT <12 mm (LV mass <99 g/m²). In contrast in female patients, LVWT ranged from 5 to 15.5 mm, LV mass ranged from 39 to 146 g/m², and LE was already detectable with an LVWT of 9 mm (LV mass 56 g/m²). When LV mass was examined in CMR, LE was detected in 23% of the female patients without hypertrophy (n = 9), whereas LE was never seen in male patients with normal LV mass. LE was always associated with low systolic strain rate, but the severity of impairment was independent of LVWT in female patients (lateral strain rate in patients with LV hypertrophy with LE -0.7 ± 0.2 s⁻¹; patients without LV hypertrophy with LE -0.8 ± 0.2 s⁻¹; p = 0.45).

CONCLUSIONS In contrast to male patients, the loss of myocardial function and the development of fibrosis do not necessarily require myocardial hypertrophy in female patients with Fabry disease. Thus, in contrast to actual recommendations, initial cardiac staging and monitoring should be based on LV hypertrophy and on replacement fibrosis in female patients with Fabry disease. (J Am Coll Cardiol Img 2011;4:592–601) © 2011 by the American College of Cardiology Foundation

From the *Department of Internal Medicine I, University of Würzburg, Würzburg, Germany; †Comprehensive Heart Failure Center, University of Würzburg, Würzburg, Germany; and the ‡Institute of Radiology, University of Würzburg, Würzburg, Germany. Drs. Niemann, Strotmann, Wanner, and Weidemann have received speakers honoraria from Genzyme. Dr. Wanner has received research grants from Genzyme not associated with this study. All other authors have reported that they have no relationships to disclose.

Manuscript received July 7, 2010; revised manuscript received November 29, 2010, accepted January 6, 2011.

Fabry disease is a lysosomal storage disorder caused by a deficiency of alpha-galactosidase A. Linked to the X chromosome, it was considered rare in heterozygous female carriers in the past (1). This was explained by a skewed inactivated X chromosome (Lyon hypothesis) (2). Nevertheless, it is now widely accepted that heterozygous female carriers could develop severe cardiomyopathy and other organ manifestations (3–9). In fact, two-thirds of all patients with Fabry disease are female. Hence, it is important to focus on the cardiac manifestations of Fabry disease in female patients.

Structure damage and function loss appear in the later stages of Fabry disease and could lead to organ failure (10). We previously showed in clinical studies that male patients commonly experience a sequence of loss of regional function, left ventricular (LV) hypertrophy, and subsequent with aging, myocardial replacement fibrosis, leading toward end-stage disease (11–13). It has been clearly determined in male patients that at least a moderate amount of LV hypertrophy is needed for the development of myocardial fibrosis (12,13). Only a few female patients were included in these clinical studies (11,12). Moreover, subtle methods of assessing cardiac function with echocardiography (strain rate) or detecting replacement fibrosis with cardiac magnetic resonance (CMR) (late enhancement [LE]) (11–19) have not been used in studies focusing on Fabry cardiomyopathy in female patients (8,20). Up to now, there has been no established guideline how to monitor female patients and when (at which stage of the disease) to treat these patients with cardiac involvement caused by Fabry disease. A common consensus in cardiac assessment is to start with enzyme replacement therapy (ERT) when a female patient presents with Fabry disease with the typical cardiac hypertrophy (assessed by echocardiography with an end-diastolic wall thickness of >12 mm) together with symptoms attributed to hypertrophic cardiomyopathy (12,21). Moreover, the use of CMR for noninvasive assessment is not recommended as a staging tool to characterize cardiac involvement in the guidelines (21).

The aim of the present study was to systematically evaluate cardiac involvement in female patients with Fabry disease. Thus, we compared the characteristics of Fabry cardiomyopathy in a large cohort of heterozygous female and male patients with standard echocardiography, strain rate imaging, and CMR using a cross-sectional design.

METHODS

Study population. Fifty-eight female (age 42 ± 16 years, range 10 to 71 years) and 46 male patients (age 42 ± 13 years, range 7 to 66 years) with genetically confirmed Fabry disease (consecutive, without contraindications for CMR) underwent echocardiography and CMR when they first presented at the Fabry Center Würzburg. Echocardiographic and CMR analysis were conducted blinded to the results of the corresponding technique by 2 experts in the field of echocardiography and CMR. Echocardiographic measurements were compared with those from a cohort of 27 controls. The controls were recruited from local hospital staff and their relatives. Care was taken to recruit controls with similar ages (Fabry group 42 ± 15 years vs. controls 47 ± 15 years; $p = 0.10$) and to include the same proportion of female volunteers as that for patients (Fabry 56% vs. controls 52%; $p = 0.83$). To match controls with patients, 7 (26%) of these controls had a history of isolated arterial hypertension without concomitant disease (Fabry group 26% with hypertension). The other controls had no history of cardiac or systemic disease. Controls had normal body mass index (22 ± 4 kg/m²) and heart rate (70 ± 11 beats/min). A clinical investigation program was conducted as described elsewhere (22). None of the patients with Fabry disease had received ERT before study entry. The study conformed to the principles outlined in the Declaration of Helsinki, and the locally appointed ethics committee approved the research protocol. Written informed consent was obtained from all patients or their guardians.

Standard echocardiographic measurements. Left ventricular end-diastolic and end-systolic dimensions and end-diastolic thickness of the posterior wall and the septum were measured using anatomic M-mode echocardiographic methods and parasternal LV long-axis images (3.5 MHz, GE Vingmed Vivid 7, Horten, Norway). Ejection fraction was calculated using the modified Simpson method. Blood pool pulsed Doppler of the mitral valve inflow was used to determine the ratio of early to late diastolic flow velocity and the deceleration time.

Assessment of hypertrophy. Left ventricular wall thickness (LVWT) was defined as the higher end-diastolic value of the posterior or the septal wall, measured with anatomic M-mode (this was neces-

ABBREVIATIONS AND ACRONYMS

ERT = enzyme replacement therapy
FD = Fabry disease
LE = late enhancement
LV = left ventricle/ventricular
LVWT = left ventricular wall thickness

Table 1. Characteristics of Female and Male Patients With Fabry Disease and Controls

	Female Controls (n = 14)	Female Patients (n = 58)	Male Controls (n = 13)	Male Patients (n = 46)
Age, yrs	49 ± 17	42 ± 16	46 ± 12	42 ± 13
BMI, kg/m ²	21.7 ± 3.4	23.5 ± 4.8	22.6 ± 3.7	22.2 ± 3.5
HR, beats/min	69 ± 11	65 ± 14	71 ± 11	65 ± 13
Systolic BP, mm Hg	125 ± 10	123 ± 16	121 ± 9	126 ± 19
Diastolic BP, mm Hg	76 ± 6	77 ± 18	78 ± 8	82 ± 10
Arterial hypertension*	3 (21)	10 (17)	4 (31)	16 (35)
Proteinuria	N/A	24 (41%)	N/A	28 (61%)
GFR, ml/min/1.73 m ²	99 ± 16	103 ± 29	95 ± 19	69 ± 46†‡§
Hemoglobin, g/dl	13.7 ± 0.7	13.1 ± 1.2	15.8 ± 1†‡	13.7 ± 1.3§

Data are presented as mean ± SD or n (%). *Arterial hypertension defined as systolic BP >140 mm Hg or diastolic BP >90 mm Hg. †p < 0.05 versus female controls. ‡p < 0.05 versus female patients. §p < 0.05 versus male controls.
BMI = body mass index; BP = blood pressure; GFR = glomerular filtration rate; HR = heart rate; N/A = not available.

sary because of the known thinning of the posterior wall in male patients having end-stage disease) (23). Following guidelines and publications for diagnosing and monitoring Fabry disease, LV hypertrophy was defined as a diastolic LVWT greater than 12 mm (12,21). However, the gold standard for myocardial mass is CMR. Thus, we also calculated myocardial mass by cine CMR indexed to body surface area (BSA) and took age and gender into account as recommended in recently published reports (24–26). Analysis of LV mass was performed by manual segmentation of the endocardial and epicardial borders of the end-diastolic and end-systolic frames as previously described (27).

Strain rate imaging. Real-time 2-dimensional color Doppler myocardial imaging data were recorded from the interventricular septum and the LV lateral wall using standard apical 4-chamber views to evaluate longitudinal function (3.5 MHz, GE Vingmed Vivid 7). For assessment of radial function of the posterior wall, parasternal long-axis views were used. Data from color Doppler myocar-

dial imaging were analyzed using dedicated software (Echopac, GE Ultrasound). Radial strain rate curves of the mid-basal posterior wall and longitudinal strain rate curves of the mid-apical septum and basal-mid lateral wall were extracted, as recommended in recent reports (14,16,28). Peak systolic strain rate (SR_{SYS}) was derived from the resulting strain rate curves.

Assessment of fibrosis. CMR with injection of gadopentetate dimeglumine 0.2 mmol/kg (Magnevist, Schering AG, Berlin, Germany) was carried out in all 104 patients on a 1.5-T scanner (Magnetom VISION, Siemens Medical Systems, Erlangen, Germany). The LE technique (8-mm slice thickness, breath hold, short heart axis) was applied to detect changes of tissue integrity in the LV myocardium. Images were acquired using an inversion recovery sequence (field of view 240 × 320 mm², matrix 165 × 256, repetition time 7.5 ms, echo time 3.4 ms, flip angle 25°, inversion time determined individually). Short-axis views at the basal, mid, and apical segments, covering the entire ven-

Table 2. Echocardiographic Parameters of Female and Male Patients With Fabry Disease and Controls

	Female Controls (n = 14)	Female Patients (n = 58)	Male Controls (n = 13)	Male Patients (n = 46)
Radial SR, s ⁻¹	2.5 ± 0.6	2.9 ± 1.1	3.0 ± 0.4	2.8 ± 1.2
Septal SR, s ⁻¹	-1.3 ± 0.3	-1.5 ± 0.4	-1.2 ± 0.3	-1.3 ± 0.5
Lateral SR, s ⁻¹	-1.3 ± 0.2	-1.2 ± 0.4	-1.3 ± 0.2	-1.1 ± 0.5
LVWT, mm	8.8 ± 1.7	9.8 ± 2.6	9.5 ± 1.8	13.5 ± 2.6*†‡
LVEDD, mm	47 ± 6	46 ± 5	50 ± 6†	50 ± 6†
LVESD, mm	31 ± 5	32 ± 6	32 ± 4	32 ± 5
EF, %	64 ± 6	64 ± 6	64 ± 4	62 ± 6
E/A	1.2 ± 0.5	1.4 ± 0.4	1.2 ± 0.5	1.3 ± 0.4
DT, ms	205 ± 62	192 ± 50	225 ± 62	219 ± 64

Data are presented as mean ± SD. *p < 0.05 versus female controls. †p < 0.05 versus female patients. ‡p < 0.05 versus male controls.
DT = deceleration time; E/A = ratio of early to late diastolic flow velocity; EF = ejection fraction; LV = left ventricular; LVEDD = left ventricular end-diastolic diameter; LVESD = left ventricular end-systolic diameter; LVWT = left ventricular wall thickness; SR = strain rate.

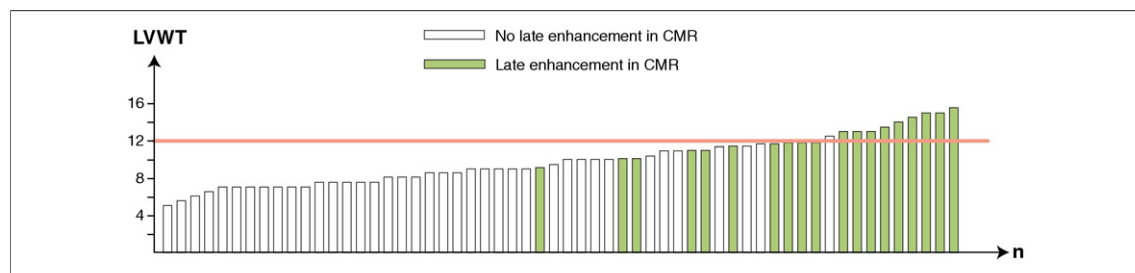


Figure 1. Distribution of LE Depending on LVWT in Female Patients With Fabry Disease

Each bar symbolizes a single patient. Patients showing late enhancement (LE) are **green bars**. The patients are shown in the order of their left ventricular wall thickness (LVWT), the y-axis displaying the amount of end-diastolic LVWT. The **pink line** indicates the border toward LV hypertrophy. Note that some female patients were already LE positive (**green bars**) without being hypertrophic. CMR = cardiac magnetic resonance.

tricle, were used for the quantitative assessment of LE (if present) by manual tracing of the LE area. Using this LE technique, every LV segment, using the standard 17-segment model, was evaluated for the occurrence of myocardial replacement fibrosis. A ratio of LE to complete LV cardiac mass was calculated.

Subgroup analysis. For advanced analysis, the patients of each sex were divided in 2 groups: the ones with hypertrophy and those without. Thereafter, these groups were further divided into fibrosis and nonfibrosis groups (4 groups for each sex). This was done for echocardiographic and CMR hypertrophy assessments separately.

Data analysis. Data are presented as mean \pm SD or as absolute patient numbers. Differences between the groups were tested using an unpaired *t* test or analysis of variance (1-way or 2-way) or multivariate analysis of variance with the Duncan post hoc test as indicated. Fisher exact test was used for categorical variables. A value of $p < 0.05$ was considered statistically significant. Statistical tests were not performed in 2 subgroups with echocardiographic LV hypertrophy assessment (female pa-

tients with hypertrophy but without fibrosis and male patients without hypertrophy but with fibrosis) because of low patient numbers. Statistica version 8.0 (StatSoft GmbH, Hamburg, Germany) was used.

RESULTS

Fabry cohort. Between October 2001 and October 2008, a total of 104 consecutive patients (58 females and 46 males) with genetically proven Fabry disease were included in this study. The characteristics of the patients with Fabry disease and controls are given in [Table 1](#). Patients and controls are subdivided by sex. Ten female and 16 male patients had a history of mild hypertension; all were normotensive at study entry under antihypertensive drug therapy.

Echocardiography. The echocardiographic parameters of patients with Fabry disease and controls are given in [Table 2](#). Patients and controls are subdivided by sex. The ejection fraction and diastolic parameters did not differ between female and male patients and respective sex-matched controls. The

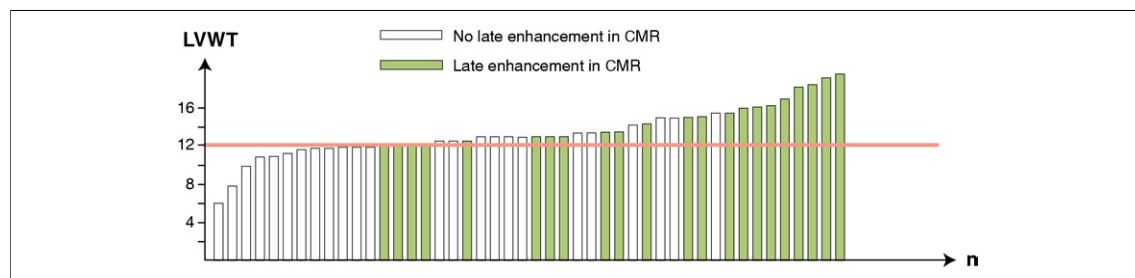


Figure 2. Distribution of LE Depending on LVWT in Male Patients With Fabry Disease

Each bar symbolizes a single patient. Patients showing LE are **green bars**. The patients are shown in the order of their LVWT, the y-axis displaying the amount of end-diastolic LVWT. The **pink line** indicates the border toward LV hypertrophy. Note that male patients are only LE positive if they have an LVWT ≥ 12 mm and that male patients develop a larger amount of LV hypertrophy compared with female patients ([Fig. 1](#)). Abbreviations as in [Figure 1](#).

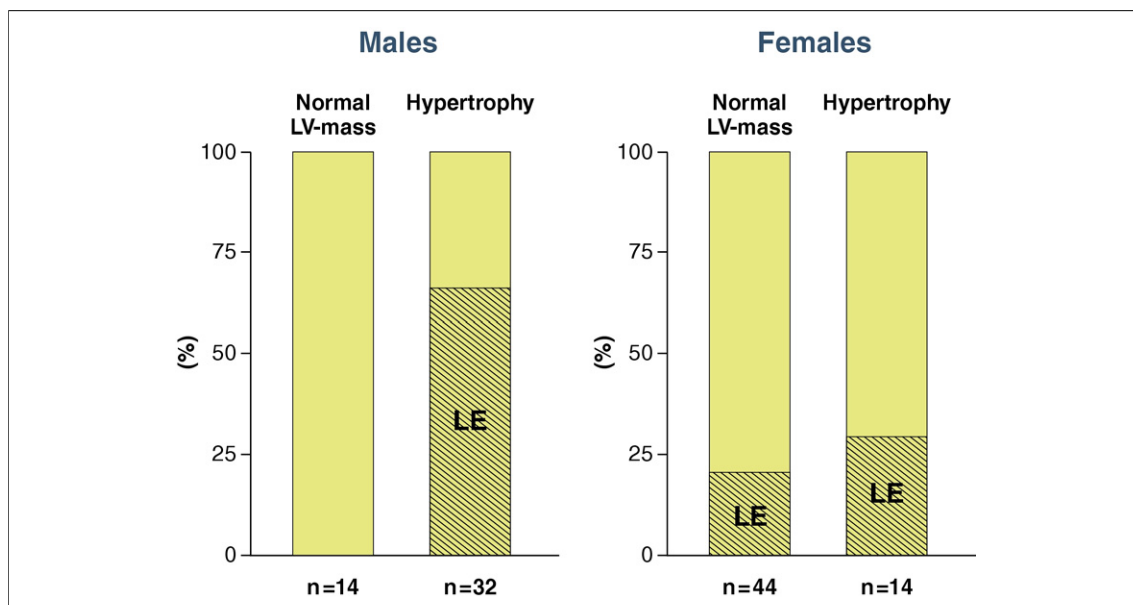


Figure 3. Distribution of LE Regarding LV Mass by CMR Indexed to Body Surface Area

Male patients are displayed on the **left** and female patients on the **right**. The patients were classified using LV mass assessed by CMR indexed to body surface area according to the hypertrophy criteria suggested by Alfakih *et al.* (25) and Cain *et al.* (26) (for adults and adolescents, respectively). The patients with ≥ 1 LE-positive segment (percentage) are shown in each group by **shaded bars**. Note that none of the male patients with normal LV-mass showed LE, whereas one-fourth of the female patients with normal LV mass showed LE. Abbreviations as in Figure 1.

LV diameters were in the normal range in all groups.

WALL THICKNESS AND MASS. The LVWT was significantly higher in male patients with Fabry disease than in the 3 other groups (male controls, female controls, female patients), who showed similar LVWT (Table 2). In the 58 female patients, LVWT ranged from 5 to 15.5 mm (LV mass CMR 39 to 146 g/m²). In the male patients (n = 46), LVWT ranged from 6 to 19.5 mm (LV mass CMR 55 to 200 g/m²). According to Fabry guideline criteria, 48 female patients showed no LV hypertrophy and only 10 female patients had LV hypertrophy (Fig. 1). In contrast, a large number of male patients had LV hypertrophy (n = 30), and only 16

male patients showed no LV hypertrophy ($p < 0.001$) (Fig. 2).

Fibrosis. LE was detected in 33% of the female (n = 19) and 48% of the male (n = 22; $p = 0.16$) patients. In CMR LE in female patients consistently occurred in the basal posterolateral wall (n = 19). The septal basal segment showed additional LE in 2 female patients, whereas fibrosis was not found in any other segments. In male patients, 22 LE segments were found in the basal posterolateral wall, 8 in anterior septal basal segments, and 1 in the mid septum. When the extension of LE within the wall was examined, 28 patients showed a localized mid myocardial LE in the typical location: lateral-basal. Two patients had additional endocardial fibrosis lateral-basal, and 1 patient

Table 3. Group Characteristics of Female Patients With Fabry Disease According to Fibrosis (by CMR) and LV Hypertrophy (by Echocardiographic Wall Thickness)

	No Hypertrophy/No Fibrosis (n = 38)	No Hypertrophy/Fibrosis + (n = 10)	Hypertrophy +/No Fibrosis (n = 1)	Hypertrophy +/Fibrosis + (n = 9)
Radial SR, s ⁻¹	3.5 ± 0.9	1.9 ± 0.6*	2.7	1.9 ± 0.6*
Septal SR, s ⁻¹	-1.5 ± 0.4	-1.4 ± 0.3	-1.4	-1.4 ± 0.3
Lateral SR, s ⁻¹	-1.4 ± 0.3	-0.8 ± 0.2*	-1.9	-0.7 ± 0.2*
LVWT, mm	8.5 ± 1.8	10.9 ± 1.0*	12.5	14.1 ± 1.0*†
LV mass CMR, g/m ²	60 ± 12	64 ± 5	91.0	100 ± 25*†

Data are presented as mean ± SD. * $p < 0.05$ versus no hypertrophy/no fibrosis group. † $p < 0.05$ versus no hypertrophy/fibrosis + group. CMR = cardiac magnetic resonance; other abbreviations as in Table 2.

Table 4. Group Characteristics of Male Patients With Fabry Disease According to Fibrosis (by CMR) and LV Hypertrophy (by Echocardiographic Wall Thickness)

	No Hypertrophy/No Fibrosis (n = 12)	No Hypertrophy/Fibrosis + (n = 4)	Hypertrophy +/No Fibrosis (n = 12)	Hypertrophy +/Fibrosis + (n = 18)
Radial SR, s ⁻¹	3.9 ± 1.2	2.6 ± 0.8	2.8 ± 0.7	2.1 ± 1.0*
Septal SR, s ⁻¹	-1.4 ± 0.4	-1.8 ± 0.5*	-1.4 ± 0.3†	-1.2 ± 0.6†
Lateral SR, s ⁻¹	-1.5 ± 0.7	-0.9 ± 0.4*	-1.1 ± 0.3	-0.8 ± 0.4*‡
LVWT, mm	10.8 ± 2.0	12.0 ± 0	13.6 ± 1.0*	15.5 ± 2.2*†
LV mass CMR, g/m ²	78 ± 15	81 ± 11	91 ± 13	122 ± 49*†‡

Data are presented as mean ± SD. *p < 0.05 versus no hypertrophy/no fibrosis group. †p < 0.05 versus no hypertrophy/fibrosis + group. ‡p < 0.05 versus hypertrophy +/no fibrosis group. Abbreviations as in Tables 2 and 3.

showed epicardial fibrosis. In 10 patients, transmural LE was observed.

In female patients, LE-positive segments were already detectable at an LVWT of 9 mm (female patient with lowest LV mass CMR and LE: 56 g/m²; limit for hypertrophy in this patient >77 g/m²), and 10 female patients without hypertrophy already presented LE-positive segments (Fig. 1). In contrast, LE was not found in male patients with LVWT <12 mm (male patient with lowest LV mass and LE: 99 g/m²) (Fig. 2). Only 1 female patient with echocardiographic hypertrophy (LVWT 12.5 mm) showed no fibrosis, whereas 12 male patients (40%) had LV hypertrophy and did not present fibrotic segments. Fibrosis was detected in all female patients with LVWT ≥13 mm and in all male patients with LVWT ≥16 mm (p = 0.04 for Fisher exact test between male and female patients LVWT ≥13 mm) (Figs. 1 and 2).

In the 10 female patients without LV hypertrophy but with fibrosis, no wall motion abnormality was detected with echocardiography. Even when these 10 patients were reanalyzed with the CMR results (having fibrosis), no wall motion abnormality could be seen in echocardiography. None of the 10 patients without hypertrophy but with fibrosis had complained about heart failure symptoms in the past, and they were referred to our center because of family screening (n = 7) and neuropathic pain (n = 3). Nevertheless, these patients only reached 75 ± 11% of their calcu-

lated target workload when performing a bicycle stress test, whereas the female patients without LV hypertrophy and without LV fibrosis reached their target with 109 ± 24% power (p = 0.002).

When hypertrophy was re-evaluated by quantification of LV mass with CMR (indexed to BSA), 9 of 10 female patients (with LE-positive segments and initially classified by echocardiographic wall thickness as LV nonhypertrophic) showed normal LV mass (Fig. 3). Only 1 of these female patients showed an LV mass above the limit (81 g/m²). In concordance with the assessment of LVWT, LE was present in 23% of the female patients with normal LV mass (indexed to BSA, with consideration of age and sex); in contrast, no LE was seen in male patients with normal LV mass (Fig. 3).

The mean extent of myocardial fibrosis was 2.4 ± 3.8% (range 0.2% to 21.4%) of the complete myocardium. In female patients, the extent of myocardial fibrosis was 1.8 ± 1.7%; in male patients, it was 2.8 ± 4.8% (p = 0.45). There was no difference in the amount of LE in female patients with or without hypertrophy: 2.4 ± 0.7% versus 2.2 ± 2.2%, respectively (p = 0.32).

Regional myocardial function. SR_{SYS} values were similar among all groups (female and male patients and female and male controls), as presented in Table 2. Echocardiographic subgroup analysis (Tables 3 and 4) showed that the female patients without hypertrophy and without fibrosis (n = 38)

Table 5. Group Characteristics of Female Patients With Fabry Disease According to Fibrosis and LV Hypertrophy (Both by CMR)

	No Hypertrophy/No Fibrosis (n = 35)	No Hypertrophy/Fibrosis + (n = 9)	Hypertrophy +/No Fibrosis (n = 4)	Hypertrophy +/Fibrosis + (n = 10)
Radial SR, s ⁻¹	3.6 ± 0.9	1.9 ± 0.6*	2.8 ± 0.8†	2.0 ± 0.6*
Septal SR, s ⁻¹	-1.5 ± 0.4	-1.4 ± 0.4	-1.3 ± 0.2	-1.4 ± 0.3
Lateral SR, s ⁻¹	-1.4 ± 0.4	-0.8 ± 0.2*	-1.1 ± 0.1	-0.7 ± 0.2*‡
LVWT, mm	8.4 ± 1.8	10.9 ± 1.1*	11.3 ± 0.5*	14.1 ± 1.2*†‡
LV mass CMR, g/m ²	56 ± 8	62 ± 4	82 ± 9*†	98 ± 24*†‡

Data are presented as mean ± SD. *p < 0.05 versus no hypertrophy/no fibrosis group. †p < 0.05 versus no hypertrophy/fibrosis + group. ‡p < 0.05 versus hypertrophy +/no fibrosis group. Abbreviations as in Tables 2 and 3.

Table 6. Group Characteristics of Male Patients With Fabry Disease According to Fibrosis and LV Hypertrophy (Both by CMR)

	No Hypertrophy/No Fibrosis (n = 14)	No Hypertrophy/Fibrosis + (n = 0)	Hypertrophy +/No Fibrosis (n = 11)	Hypertrophy +/Fibrosis + (n = 21)
Radial SR, s ⁻¹	3.4 ± 1.3	—	3.2 ± 0.9	2.2 ± 1.0*
Septal SR, s ⁻¹	-1.3 ± 0.4	—	-1.4 ± 0.2	-1.3 ± 0.6
Lateral SR, s ⁻¹	-1.3 ± 0.4	—	-1.3 ± 0.7	-0.8 ± 0.4*†
LVWT, mm	11.1 ± 2.2	—	13.5 ± 1.1*	15.4 ± 2.9*
LV mass CMR, g/m ²	74 ± 10	—	98 ± 8*	125 ± 36*†

Data are presented as mean ± SD. *p < 0.05 versus no hypertrophy/no fibrosis group. †p < 0.05 versus hypertrophy +/no fibrosis group. Abbreviations as in Tables 2 and 3.

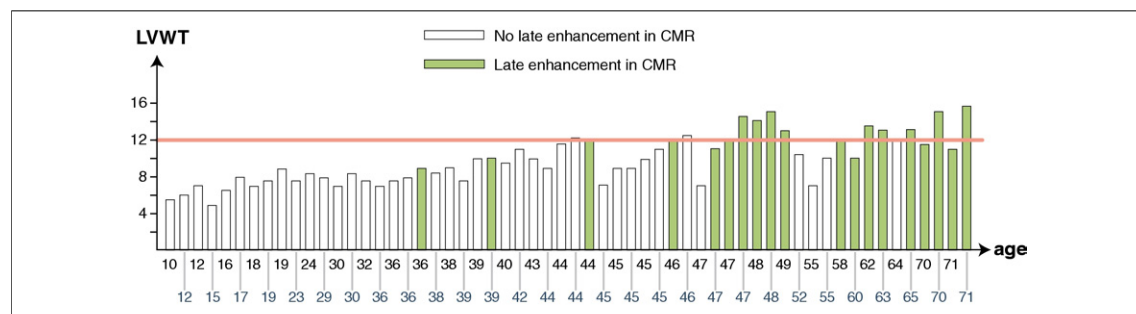
had a significantly higher regional myocardial function than the 2 female groups with fibrosis. There was no difference in myocardial function in these 2 groups with fibrosis, although the LVWT and LV CMR mass were significantly different (Table 3). The comparison of the LV hypertrophic male patients with (n = 18) and without fibrosis (n = 12) showed that the group with fibrosis had lower radial and longitudinal SR_{SYS} values (Table 4). In male patients, the highest SR_{SYS} values were found in the patient group without both LV hypertrophy and fibrosis. Myocardial function was similar in male and female subgroups with comparable LE and hypertrophy conditions (Tables 3 and 4). Tables 5 and 6 provide the same subgroup analysis presented in Tables 3 and 4 but with hypertrophy assessed by CMR (LV mass) instead of echocardiography. In general, the same findings as in the echocardiographic subanalysis could be detected. The data in Table 5 confirm the echocardiographic finding that female patients without hypertrophy (normal LV mass in CMR) show LE.

Age and morphological changes. The distribution of LVWT and LE in relation to age is shown in Figures 4 (female patients) and 5 (male patients). The youngest female patient with LE was 36 years

of age, and the youngest male patient with LE was 23 years of age. Even a 20-year-old male patient showed hypertrophy, whereas hypertrophy was not seen in female patients before the age of 46 years. Thus, in our female cohort, LE occurred earlier than LV hypertrophy. LE was not detected in 4 of 13 female patients (31%) and 2 of 12 male patients (17%) older than 50 years (p = 0.65).

DISCUSSION

This study is the first systematic single-center investigation using subtle methods like strain rate imaging and CMR to highlight cardiomyopathy in female patients with Fabry disease. With a cross-sectional study design in a large Fabry cohort, the main results obtained were: 1) in 34% of the complete Fabry female cohort, signs of cardiomyopathy (hypertrophy or fibrosis) were found; 2) in contrast to male patients, there was no fixed linkage of hypertrophy and fibrosis in female patients with Fabry disease (e.g., female patients can develop some replacement fibrosis without being hypertrophic); and 3) 50% of the female patients with signs of relevant cardiomyopathy would not have been detected by the guideline-proposed standard echocardiographic and LV hypertrophy assessment.

**Figure 4. Distribution of LE Depending on Age in Female Patients With Fabry Disease**

Each bar symbolizes a single patient. Patients showing LE are green bars. The patients are sorted in the order of their age. The y-axis displays the amount of end-diastolic LVWT. The pink line indicates the border toward LV hypertrophy. Note that some younger female patients who were nonhypertrophic already showed LE and some older patients did not show cardiac involvement at all. Abbreviations as in Figure 1.

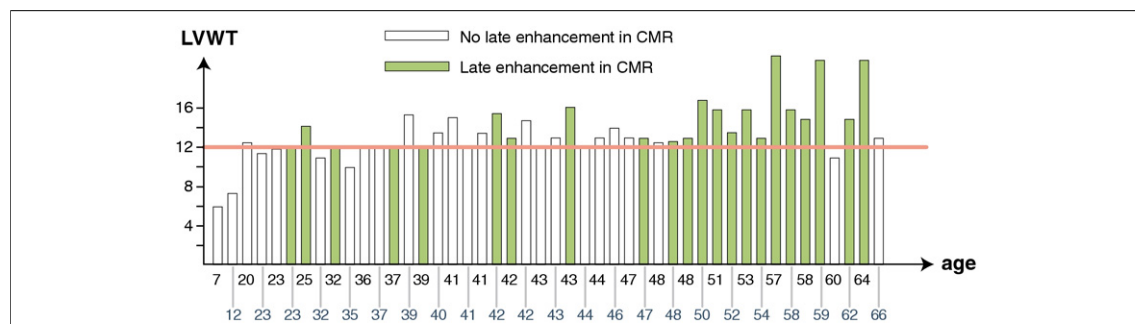


Figure 5. Distribution of LE Depending on Age in Male Patients With Fabry Disease

Each bar symbolizes a single patient. Patients showing LE are green bars. The patients are sorted in the order of their age. The y-axis displays the amount of end-diastolic LVWT. The pink line indicates the border toward LV hypertrophy. Note that the onset of LE according to age in male patients was earlier than that in female patients. Abbreviations as in Figure 1.

Female Fabry cardiomyopathy. From previous studies, it is known that the morphological hallmarks of Fabry cardiomyopathy are LV hypertrophy and replacement fibrosis, which are both consistent with the finding of reduced regional LV function. In male patients, the LV starts to hypertrophy during adolescence; this is accompanied by reduced longitudinal function (12,13,17,18). The hypertrophy in these male patients progresses quite fast and finally leads to replacement fibrosis (12–14). Both the typical Fabry cardiomyopathy findings and the described temporal sequence were also evident in our male cohort. In contrast, the fixed linkage of hypertrophy and fibrosis seemed to be not applicable for female patients with Fabry disease, although in general the same hallmarks (i.e., hypertrophy, reduced regional myocardial function, and replacement fibrosis) can be detected in the hearts of most female patients with Fabry cardiomyopathy. Thus, it seems that in our cohort, the progression toward severe hypertrophy in female patients was prolonged because of the residual activity of alpha-galactosidase A (caused by the random inactivation of the mutated or nonmutated X chromosome). This is in concordance with previous studies done by Goldman *et al.* (29) and Linhart *et al.* (30), showing that LV hypertrophy is more common in male than in female patients. However, despite the delayed development of hypertrophy, fibrosis seems to progress continuously. Therefore, as shown in the current study, replacement fibrosis can already be present in the female heart with Fabry disease at a nonhypertrophic disease stage (Fig. 6). In addition, it could be shown that in all hearts that progress toward LV hypertrophy, replacement fibrosis is an integral component of Fabry cardiomyopathy in female patients. As expected, regional LV function was significantly reduced in the fibrotic

segments. Interestingly, this reduction of regional longitudinal function was independent of the degree of hypertrophy. This might lead to the speculation that in general regional myocardial function in Fabry cardiomyopathy could be more related to tissue fibrosis and less to hypertrophy. Furthermore, some female patients with Fabry disease obviously have a compensatory mechanism that protects the heart even in advanced age from developing typical cardiomyopathy. However, it is impossible to decide whether the differences between male and female patients might be due to an altered temporal sequence of cardiomyopathy in female patients (a




Figure 6. Echocardiographic and CMR Images of a Female Patient Without LV Hypertrophy but With LE

(A) Short-axis echocardiographic view. (B) 4-chamber echocardiographic view. The LV cavity is marked with LV. The images clearly show that no LV hypertrophy is present. (C) Short-axis view of the same patient using the LE technique by CMR. (D) 4-chamber CMR view. The arrows indicate LE in the lateral wall. Abbreviations as in Figures 1 and 2.

“speculative” model is given in Fig. 7) or due to phenotypical variability.

Clinical implications. These findings might have implications for the initial staging and cardiac monitoring of female patients with Fabry disease. In general, the progression toward cardiomyopathy is monitored by echocardiographic assessment of end-diastolic LVWT; in contrast, CMR and strain rate imaging is often proposed to be optional (21). Thus, by this approach, one-half of the Fabry cardiomyopathy in our female cohort would have not been detected. It was shown in a previous report that strain rate imaging helps to identify male patients with subclinical Fabry cardiomyopathy presenting without LV hypertrophy (18). However, the findings of our present study emphasize that especially in female patients, CMR

with LE imaging is necessary to evaluate cardiomyopathy. This is emphasized by the fact that even with the knowledge of LE in none of the female patients without LV hypertrophy but with LE, a wall motion abnormality could be identified with echocardiography. In addition, as known from previous work, only patients without cardiac fibrosis will profit in the long term from ERT (12). Thus, the assessment of fibrosis in female Fabry patients might guide therapy initiation and might have implications for treatment expectations.

In patients contraindicated for CMR, strain rate imaging might be of advantage for the functional assessment of cardiomyopathy-related fibrosis (31).

By genetic definition, two-thirds of all Fabry patients are female; therefore, cardiologists have to be aware of characteristic Fabry cardiomyopathy in female patients. This is an upcoming challenge because a lot of uncharacterized and untreated female patients have been found in screening studies and by subsequent family screening in the last years.

Study limitations. In principle, longitudinal data are necessary to describe the temporal sequence of cardiomyopathy progression. However, the large cohort of patients with a standardized evaluation should be sufficient to allow an approximate description of the temporal sequence of the cardiac disease. We did not aim to clarify disease progression in female patients with this study but wanted to emphasize that in female patients, the diagnostic approach toward cardiomyopathy has to include CMR with LE imaging. Thus, the aim was to emphasize the importance of noninvasive assessment of myocardial fibrosis in female patients with Fabry disease.

For ethical reasons, we did not undertake myocardial biopsies in the patients to determine the underlying histological morphology.

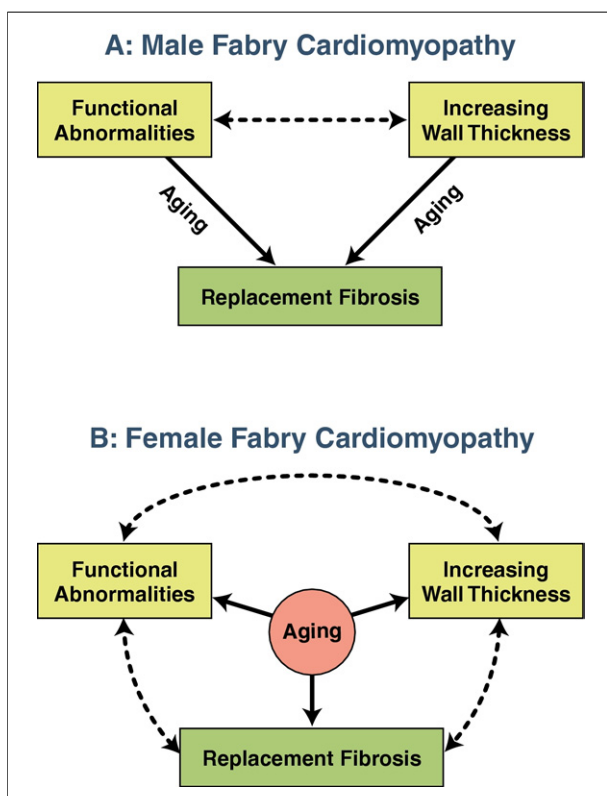


Figure 7. Cardiomyopathy Disease Progression in Male and Female Patients With Fabry Disease

The hallmarks of Fabry cardiomyopathy (increasing wall thickness, regional functional abnormalities, and replacement fibrosis) are used to describe the disease progression during aging of both sexes. (A) In male patients, the LV starts to hypertrophy during adolescence, and this is accompanied by reduced longitudinal function. During aging, these 2 features lead to replacement fibrosis. (B) Cardiomyopathy disease progression in female patients is different. In contrast to male patients, the 3 hallmarks cannot be described as a temporal sequence toward fibrosis. In contrast, it is more a vicious circle: the progression toward hypertrophy is prolonged, whereas the development of fibrosis and regional functional abnormalities progresses simultaneously. Abbreviations as in Figure 1.

CONCLUSIONS

Fabry cardiomyopathy in female patients differs from that in male patients. Female patients can develop fibrosis without showing LV hypertrophy. Therefore, staging and monitoring female patients with Fabry disease should routinely include the assessment of replacement fibrosis. Moreover, new treatment indications for female patients with Fabry disease seem to be needed.

Reprint requests and correspondence: Prof. Dr. Frank Weidemann, Medizinische Klinik und Poliklinik I, Zentrum für Innere Medizin, Oberdürrbacher Str. 6, 97080 Würzburg, Germany. E-mail: weidemann_f@medizin.uni-wuerzburg.de.

REFERENCES

1. Desnick R, Ionnoy Y, Eng C. Fabry disease: alpha galactosidase A deficiency. In: Scriver C, Beaudet A, Sly W, Valle D, editors. *The Metabolic and Molecular Bases of Inherited Disease*. New York, NY: McGraw Hill, 1995:2741-84.
2. Ropers HH, Wienker TF, Grimm T, Schroetter K, Bender K. Evidence for preferential X-chromosome inactivation in a family with Fabry disease. *Am J Hum Genet* 1977;29:361-70.
3. MacDermot KD, Holmes A, Miners AH. Anderson-Fabry disease: clinical manifestations and impact of disease in a cohort of 60 obligate carrier females. *J Med Genet* 2001;38:769-75.
4. MacDermot KD, Holmes A, Miners AH. Natural history of Fabry disease in affected males and obligate carrier females. *J Inher Metab Dis* 2001;24 Suppl 2:13-4, discussion 11-2.
5. Moller AT, Jensen TS. Neurological manifestations in Fabry's disease. *Nat Clin Pract Neurol* 2007;3:95-106.
6. Moller AT, Feldt-Rasmussen U, Rasmussen AK, et al. Small-fibre neuropathy in female Fabry patients: reduced allodynia and skin blood flow after topical capsaicin. *J Peripher Nerv Syst* 2006;11:119-25.
7. Mehta A, Ricci R, Widmer U, et al. Fabry disease defined: baseline clinical manifestations of 366 patients in the Fabry Outcome Survey. *Eur J Clin Invest* 2004;34:236-42.
8. Maier EM, Osterrieder S, Whybra C, et al. Disease manifestations and X inactivation in heterozygous females with Fabry disease. *Acta Paediatr Suppl* 2006;95:30-8.
9. Linhart A, Kampmann C, Zamorano JL, et al. Cardiac manifestations of Anderson-Fabry disease: results from the international Fabry Outcome Survey. *Eur Heart J* 2007;28:1228-35.
10. Wanner C. Fabry disease model: a rational approach to the management of Fabry disease. *Clin Ther* 2007;29 Suppl A:S2-5.
11. Weidemann F, Breunig F, Beer M, et al. Improvement of cardiac function during enzyme replacement therapy in patients with Fabry disease: a prospective strain rate imaging study. *Circulation* 2003;108:1299-301.
12. Weidemann F, Niemann M, Breunig F, et al. Long-term effects of enzyme replacement therapy on Fabry cardiomyopathy: evidence for a better outcome with early treatment. *Circulation* 2009;119:524-9.
13. Weidemann F, Breunig F, Beer M, et al. The variation of morphological and functional cardiac manifestation in Fabry disease: potential implications for the time course of the disease. *Eur Heart J* 2005;26:1221-7.
14. Moon JC, Sachdev B, Elkington AG, et al. Gadolinium enhanced cardiovascular magnetic resonance in Anderson-Fabry disease. Evidence for a disease specific abnormality of the myocardial interstitium. *Eur Heart J* 2003;24:2151-5.
15. Moon JC, Sheppard M, Reed E, Lee P, Elliott PM, Pennell DJ. The histological basis of late gadolinium enhancement cardiovascular magnetic resonance in a patient with Anderson-Fabry disease. *J Cardiovasc Magn Reson* 2006;8:479-82.
16. Beer M, Weidemann F, Breunig F, et al. Impact of enzyme replacement therapy on cardiac morphology and function and late enhancement in Fabry's cardiomyopathy. *Am J Cardiol* 2006;97:1515-8.
17. Pieroni M, Chimenti C, Russo A, Russo MA, Maseri A, Frustaci A. Tissue Doppler imaging in Fabry disease. *Curr Opin Cardiol* 2004;19:452-7.
18. Pieroni M, Chimenti C, Ricci R, Sale P, Russo MA, Frustaci A. Early detection of Fabry cardiomyopathy by tissue Doppler imaging. *Circulation* 2003;107:1978-84.
19. Gange CA, Link MS, Maron MS. Utility of cardiovascular magnetic resonance in the diagnosis of Anderson-Fabry disease. *Circulation* 2009;120:e96-7.
20. Kampmann C, Baehner F, Whybra C, et al. Cardiac manifestations of Anderson-Fabry disease in heterozygous females. *J Am Coll Cardiol* 2002;40:1668-74.
21. Eng CM, Germain DP, Banikazemi M, et al. Fabry disease: guidelines for the evaluation and management of multi-organ system involvement. *Genet Med* 2006;8:539-48.
22. Breunig F, Weidemann F, Beer M, et al. Fabry disease: diagnosis and treatment. *Kidney Int Suppl* 2003;63 Suppl 84: S181-5.
23. Takenaka T, Teraguchi H, Yoshida A, et al. Terminal stage cardiac findings in patients with cardiac Fabry disease: an electrocardiographic, echocardiographic, and autopsy study. *J Cardiol* 2008;51:50-9.
24. Alfakih K, Plein S, Thiele H, Jones T, Ridgway JP, Sivanathan MU. Normal human left and right ventricular dimensions for MRI as assessed by turbo gradient echo and steady-state free precession imaging sequences. *J Magn Reson Imaging* 2003;17:323-9.
25. Alfakih K, Reid S, Jones T, Sivanathan M. Assessment of ventricular function and mass by cardiac magnetic resonance imaging. *Eur Radiol* 2004;14:1813-22.
26. Cain PA, Ahl R, Hedstrom E, et al. Age and gender specific normal values of left ventricular mass, volume and function for gradient echo magnetic resonance imaging: a cross sectional study. *BMC Med Imaging* 2009;9:2.
27. Sandstede J, Lipke C, Beer M, et al. Age- and gender-specific differences in left and right ventricular cardiac function and mass determined by cine magnetic resonance imaging. *Eur Radiol* 2000;10:438-42.
28. Strotmann J, Weidemann F, Breunig F, Knoll A, Wanner C, Ertl G. Morbus Fabry of the heart. Why should cardiologists care? *Z Kardiol* 2005;94:557-63.
29. Goldman ME, Cantor R, Schwartz MF, Baker M, Desnick RJ. Echocardiographic abnormalities and disease severity in Fabry's disease. *J Am Coll Cardiol* 1986;7:1157-61.
30. Linhart A, Palecek T, Bultas J, et al. New insights in cardiac structural changes in patients with Fabry's disease. *Am Heart J* 2000;139:1101-8.
31. Weidemann F, Niemann M, Herrmann S, et al. A new echocardiographic approach for the detection of non-ischaemic fibrosis in hypertrophic myocardium. *Eur Heart J* 2007;28:3020-6.

Key Words: cardiomyopathy ■ echocardiography ■ Fabry disease ■ hypertrophy.