

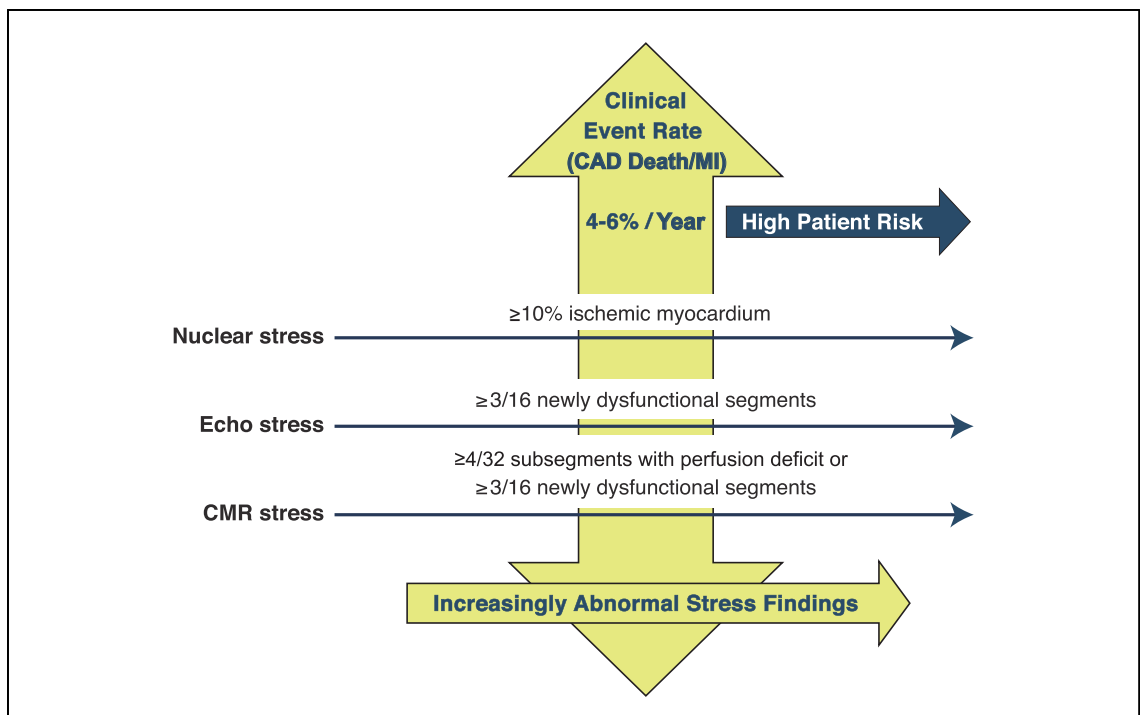
CORRECTION

Shaw LJ, Berman DS, Picard MH, Friedrich MG, Kwong RY, Stone GW, Senior R, Min JK, Hachamovitch R, Scherrer-Crosbie M, Mieres JH, Marwick TH, Phillips LM, Chaudhry FA, Pellikka PA, Slomka P, Arai AE, Iskandrian AE, Bateman TM, Heller GV, Miller TD, Nagel E, Goyal A, Borges-Neto S, Boden WE, Reynolds HR, Hochman JS, Maron DJ, Douglas PS, for the National Institutes of Health/National Heart, Lung, and Blood Institute-Sponsored ISCHEMIA Trial Investigators

Comparative Definitions for Moderate-Severe Ischemia in Stress Nuclear, Echocardiography, and Magnetic Resonance Imaging.

J Am Coll Cardiol Img 2014;7:593-604.

In Figure 4, the following line has been changed from “ $\geq 4/32$ ischemic defects” to “ $\geq 4/32$ subsegments with perfusion deficit.” The revised figure is below:



The authors apologize for this error.

<http://dx.doi.org/10.1016/j.jcmg.2014.06.003>